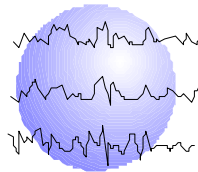


INFANT FUNCTIONAL HEMISPHERECTOMY: TECHNICAL CONSIDERATIONS, SAFETY, RESULTS

Mary E. Dunn, MD, FACS
Michael D. Frost, MD
Frank J. Ritter, MD



This paper has been prepared specifically for:

American Epilepsy Society Annual Meeting
Boston, MA
December 5 - 10, 2003

Please consider this information to be preliminary findings.

Minnesota Epilepsy Group, P.A.[®]
225 Smith Avenue N., Suite 201
St. Paul, MN 55102-2534
Phone: (651) 241-5290
Fax: (651) 241-5248

Abstract

RATIONALE:

There were 408 pediatric intracranial epilepsy procedures performed with the Minnesota Epilepsy Surgery Group at Children's Hospital of St. Paul, Minnesota between 07/01/1991 and 04/01/2003. There were 21 functional hemispherectomies in this group. Of these, four were infants less than 5 months of age.

Clinical characteristics of these infants:

1. Clinical epileptic events noted within 24 hours of birth.
2. EEG:
 - Unilateral hemispheric epileptiform discharge greater than 100 events per day in each infant.
 - Unilateral hemispheric interictal abnormality in each infant.
3. Imaging
 - MRI: Hemimeganencephaly (1), hemispheric migrational abnormality, dysplasia (3)
 - PET: Hypometabolism anomaly (2)
4. Medical Therapies initiated with failure:
 - 3+ seizures med (4)
 - ACTII (2)
 - Dietary modifications (2)

METHODS: Functional hemispherectomy as described by Rasmussen was performed in all infants. One infant, the first of these series, required a two-stage procedure three days apart due to coagulopathy. The other three had one operative intervention.

Preoperative average weight was 5.76 kg.

Average preoperative hemoglobin was 10.5

Procedure duration average was 6.5 hours (3) and 13.5 hours in the two-stage infant.

Intraoperative transfusion occurred in one infant. Postoperative transfusion at 24 hours in one infant with postoperative hemoglobin of 5.3 and no transfusion in two infants with hemoglobin greater than 5.6. These infants were given iron supplementation.

RESULTS: Average follow-up was 5 years, 8 months. All patients are off seizure medications and seizure free at follow-up. One patient (hemimeganencephaly) required reoperation with insular cortex resection at 2.5 years of age. This patient was off medications for one year and had seizure recurrence from remaining insular cortex. He has now been seizure free off medication for 5 years, 6 months.

CONCLUSION: Infants can safely undergo indicated functional hemispherectomy with minimal morbidity and excellent seizure outcome. Further discussion will include functional outcome in this group as regards Physical Therapy, Occupational Therapy, and Neuropsychological assessments.

INTRODUCTION

Pediatric epilepsy surgeons and epileptologists have been hesitant to perform hemispherectomies in small infants due to issues of blood volumes and potential complications.

Question: Can hemispherectomy be performed safely, effectively in infants?

STUDY POPULATION

There were 408 pediatric intracranial epilepsy procedures performed with the Minnesota Epilepsy Surgery Group at Children's Hospital of St. Paul, Minnesota between 07/01/1991 and 04/01/2003. There were 21 functional hemispherectomies in this group. Of these, four were infants less than 5 months of age.

CLINICAL FEATURES

1. Clinical epileptic events noted within 24 hours of birth.
2. EEG:
 - Unilateral hemispheric epileptiform discharge greater than 100 events per day in each infant.
 - Unilateral hemispheric interictal abnormality in each infant.
3. Imaging
 - MRI: Hemimegalencephaly (1), hemispheric migrational abnormality, dysplasia (3) (Fig. 1)
 - PET: Hypometabolism anomaly (2)
4. Medical Therapies initiated with failure:
 - 3+ seizures med (4)
 - ACTH (2)
 - Dietary modifications (2)
5. Preoperative average weight was 5.76 kg.
6. Average preoperative hemoglobin was 10.5

TECHNIQUE OF FUNCTIONAL HEMISPHERECTOMY

1. Large C shaped incision
2. Temporal lobectomy
3. Excision of central region
4. Insular cortex removal
5. Disconnection of parietal-occipital lobes
6. Disconnection of frontal lobe
- * 7. Subcallosal gyrus resection - genu and splenium
- * 8. Pre M, cortical resection (Fig 2)

Procedure duration average was 6.5 hours (3). The first infant with hemimegalencephaly required a two-stage procedure.

Intraoperative transfusion occurred in one infant. Postoperative transfusion at 24 hours in one infant with postoperative hemoglobin of 5.3 and no transfusion in two infants with hemoglobin greater than 5.6. These infants were given iron supplementation.

* Failure to accomplish #7 and #8 resulted in reoperation on the infant with hemimegalencephaly

RESULTS

- Average follow-up was 5 years, 8 months.
- All patients are off seizure meds and seizure free at last visit
- One patient (hemimegalencephaly) required reoperation with pre M, and subcallosal cortex resection at 2.5 years of age. He had been seizure free for one year with presumed recurrence in insular cortex. He is now seizure free and off meds for 5 years.

CONCLUSION

Infants can safely undergo indicated functional hemispherectomy with minimal morbidity and excellent seizure outcome.