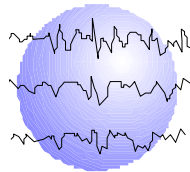


**INCOMPLETE REORGANIZATION OF LANGUAGE TO
THE RIGHT HEMISPHERE IN RESPONSE TO EARLY
LEFT HEMISPHERE SEIZURE ONSET:
IMPLICATIONS FOR LEFT HEMISPHERE FOCAL
RESECTION**

Ann Hempel, PhD
Gail L. Risse, PhD
Rosette A. Jabbour, MD
Frank J. Ritter, MD
John R. Gates, MD
Michael D. Frost, MD



This paper has been prepared specifically for:

American Epilepsy Society Annual Meeting
New Orleans, Louisiana
December 3 - 8, 2004

Please consider this information to be preliminary findings.

Minnesota Epilepsy Group, P.A.[®]
225 Smith Avenue N., Suite 201
St. Paul, MN 55102
Phone: (651) 241-5290
Fax: (651) 241-5248

ABSTRACT

RATIONALE: The intracarotid amobarbital procedure (IAP) is considered the gold standard for assessment of hemispheric dominance for language functions despite the recent development of functional imaging studies for this purpose. These methods are highly reliable when language is clearly unilateral. However, the presence of even subtle language ability in the nondominant hemisphere may place a patient at risk for postoperative aphasia. This study reports on patients who appeared primarily right hemisphere language dominant on IAP but nonetheless clearly demonstrated left hemisphere language areas during electrical stimulation studies.

METHODS: Two male and two female patients, ages 11-18 years, underwent IAP and electrical stimulation studies prior to focal resection for intractable seizures involving the left frontal or temporal area. Three of four were left-handed. IQ was mildly impaired (74-81) in all patients. All four evidenced left hemisphere structural abnormalities, and three evidenced left mesial temporal sclerosis. During cortical mapping, language was tested in five modalities (rote speech, naming, repetition, comprehension and reading). These mapping data were contrasted with the IAP.

RESULTS: All patients displayed primarily right hemispheric language dominance on IAP; however, minor language production (rote or automatic speech) was noted following right hemisphere injection in three patients, and paraphasic errors, which were sometimes subtle, were noted following left hemisphere injection in three patients. On cortical stimulation, clear frontal and temporal language areas were identified in all patients, with the exception of one patient whose subdural electrode array did not extend anterior to the motor area, precluding identification of a frontal language area.

CONCLUSION: Right hemisphere language dominant epilepsy surgery candidates with even subtle evidence of left hemisphere language on IAP should be considered for cortical mapping prior to resection.

Epilepsia 45 Suppl. 7:180 (Abst. 1.488), 2004

Introduction:

The IAP remains the gold standard for assessment of hemispheric dominance for language as research progresses on the reliability and validity of other methods, such as fMRI and magnetic source imaging. On the IAP, a hemisphere's involvement in language processing is determined by uninterrupted language processing and absence of language errors following injection of the opposite hemisphere, and is typically confirmed by global aphasia following injection of the presumed language dominant hemisphere. However, the meaning of minor deviations from this pattern of findings can be uncertain. That is, it is unclear if limited speech production following injection of the presumed dominant hemisphere or minor language errors following injection of the presumed nondominant hemisphere truly reflect some capacity of the nondominant hemisphere for language processing. The aim of the present study was to examine what on IAP appeared to be a minor role of the nondominant left hemisphere in language in a small sample of patients who were essentially right hemisphere language dominant, presumably in response to early left hemisphere injury or seizure onset.

Methods:

Patient sample: Two male and two female patients, ages 11-20 years, underwent IAP and electrical stimulation studies prior to focal resection for intractable seizures originating from the left temporal (n=3) or left frontal (n=1) region. Three of four were left-handed. Although all obtained Full Scale IQs in the mildly impaired range, three of four displayed a clear discrepancy in Verbal and Performance IQ scores in favor of verbal ability (low normal range). This is consistent with nondominant hemisphere involvement in seizure onset and suggests possible reorganization of language functions to the right hemisphere (Table 2). All patients experienced onset of their seizure disorders in early childhood (birth to 3 years) and all evidenced left hemisphere structural abnormality on MRI, which included left mesial temporal sclerosis in three. Only one patient has a close relative with atypical handedness. All underwent the IAP, which involved injection of both hemispheres on the same day. All underwent cortical mapping of language areas during electrical stimulation studies. During cortical mapping, language was tested in five modalities at each electrode pair: rote speech (counting), naming, repetition, comprehension, and reading. Cortical mapping data were contrasted with results of the IAP.

Results

IAP

Left injection: All patients displayed language performance in multiple modalities (e.g. naming, spontaneous speech, comprehension) following left hemisphere injection, although in one patient, recovery from amobarbital injection occurred quickly (as assessed by right hand motor recovery), and in this patient most aspects of language were observed after first evidence of right hand movement. Two patients displayed paraphasic errors and one other patient failed repetition items.

Right injection: One patient was obtunded, precluding valid assessment of language production in the left hemisphere. All of the remaining three patients displayed a capacity for motor speech in the early post-injection period: one uttered an automatic phrase and two uttered paraphasic errors. Only one produced clearly meaningful speech (reciting days of the week on command) prior to first evidence of left hand motor recovery.

Cortical mapping of language

A frontal language area (FLA) could not be assessed in one patient because the anterior-most boundary of the SEA extended only to the prefrontal gyrus. A temporal language area (TLA) was identified in this patient, and both frontal and temporal language areas were identified in the three other patients. Errors in more than a single modality were seen at each patient's FLA and TLA.

Discussion

Cortical language mapping confirmed residual language cortex in the nondominant hemisphere in 4 patients who displayed primarily right hemisphere language dominance on IAP. These results suggest that patients who present with early left hemisphere seizure onset and presumed reorganization of language to the right hemisphere may retain some vestigial left hemisphere language capacity. The possibility of some residual language function in the left hemisphere was suggested on IAP by either 1) minor speech production with right hemisphere injection, or 2) paraphasic errors or less than a full complement of language functions following left hemisphere injection. The potential consequences of resection of residual language cortex is unknown. However, this study suggests that right hemisphere dominant patients who display even subtle evidence of a left hemisphere capacity for language should undergo cortical language mapping prior to resection to prevent possible postoperative language decline.

Conclusions:

- Somewhat surprisingly, cortical language mapping identified both frontal and temporal language cortex in the left hemisphere in patients known to be primarily right hemisphere dominant for language on IAP.
- This study supports the value of cortical language mapping prior to left hemisphere resection to prevent possible postoperative language decline among those patients who display even minimal evidence of residual left hemisphere speech.

Table 1

Patient History

Patient	Gender	Handedness	Age at Surgery (yrs-mos.)	Age of Seizure Onset	Etiology	Family History of Left Handedness	Surgery
1	F	L	11-9	Birth	Severe L MTS	None	LTL
2	M	R	20-3	23 months	LT Cerebritis L MTS	Two 2 nd degree relatives	LTL
3	F	L	11-3	3 years	L Frontal- Parietal Tumor	One 2 nd -degree relative	LFT
4	M	L	15-2	Infancy	Mild L MTS	One ambidextrous, one left-handed 1 st degree relative	LTL
MTS=mesial temporal sclerosis L=left LTL= left temporal lobectomy			LT=left temporal LFT=left frontal topectomy				

Table 2

Patient IQ

Patient	VIQ	PIQ	FSIQ
1	76	76	74
2	86	69	75
3	87	78	81
4	90	70	78

Table 3

IAP Results

Patient	L Hemisphere Injection	R Hemisphere Injection
1	Naming Spontaneous remark Comprehension No repetition	"God dang it"
2	Naming Reading Repetition Comprehension after first spontaneous movement Paraphasic error	Paraphasic error Repetition shortly before motor recovery
3	Naming Other modalities observed shortly after first evidence of spontaneous movement	Obtunded
4	Naming Reading Repetition Rote Speech Comprehension Paraphasic errors	Counting backward when asked to name Rote speech Paraphasic errors

Table 4

Cortical Mapping of Language: Observed Language Errors

Patient	Frontal Language Area	Temporal Language Area
1	Speech arrest anterior to tongue and throat regions Slowness in comprehension	Hesitation in Naming Slowness in comprehension Errors in comprehending phonemes Naming Errors Reading Errors
2	Naming errors Comprehension Errors Partial repetition errors	Naming errors Repetition errors Reading errors Comprehension errors
3	Not assessed due to posterior SEA placement	Naming errors Repetition errors Reading errors
4	Slow Naming Slow Repetition Minor reading error	Naming errors Repetition errors Reading errors Slow reading