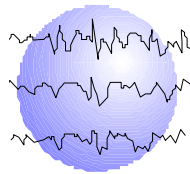


# **IS MAGNETOENCEPHALOGRAPHY/MAGNETIC SOURCE IMAGING (MSI) A RELIABLE REPLACEMENT FOR THE WADA TEST IN THE PEDIATRIC POPULATION?**

Donna L. Minter, PhD  
Wenbo Zhang, MD, PhD  
Ann Hempel, PhD  
Gretchen Weatherly, PhD  
Eduardo M. Castillo, PhD  
Michael D. Frost, MD



This paper has been prepared specifically for:

American Epilepsy Society Annual Meeting  
Washington, DC  
December 2 - 6, 2005

Please consider this information to be preliminary findings.

Minnesota Epilepsy Group, P.A.<sup>®</sup>  
225 Smith Avenue N., Suite 201  
St. Paul, MN 55102  
Phone: (651) 241-5290  
Fax: (651) 241-5248

## REVISED ABSTRACT

**RATIONALE:** For many years the intracarotid amobarbital procedure (IAP) or Wada test has been used to clarify and establish hemispheric language dominance in preparation for epilepsy surgery. Since the IAP is an invasive procedure, finding an alternative means of obtaining this information is desirable. Recently magnetoencephalography or magnetic source imaging (MSI) has shown promise as a noninvasive procedure to establish language dominance. However, studies of the relationship between IAP results and MSI findings are few to date, and this is particularly true for the pediatric population. This study reports preliminary data comparing these procedures.

**METHODS:** A retrospective chart review was conducted of pediatric patients with intractable seizures from the Minnesota Epilepsy Group who had both IAP and MSI language activation studies since 1998. The IAP was conducted at the Minnesota Epilepsy Group and the MSI study was done either at the Minnesota Epilepsy Group or the University of Texas Houston Health Science Center using established protocols. Eleven subjects (9 males and 2 females) were studied in this initial comparison. Ages ranged from 6-17 years. All subjects had the two procedures within 12 months of each other.

**RESULTS:** The IAP and MSI strict concordance rate was 64% (7 of 11) with four subjects classified with left language dominance on both IAP and MSI and two subjects classified for bilateral language on both IAP and MSI. One subject was right dominant on the MSI and had bilateral language representation on the IAP. The remaining three subjects had bilateral MSI findings but were left dominant on IAP. None of the cases were completely discordant by showing opposite findings on the two procedures. Nine of the eleven subjects (82%) had agreement of the presence or absence of language with regard to the hemisphere to be treated.

**CONCLUSION:** These preliminary data suggest some difficulty in consistently identifying subjects with bilateral language findings using both IAP and MSI. However, there was a similar higher level of agreement between the two methods when identifying the presence or absence of language in the hemisphere of proposed surgery. While there were no truly discordant cases reported (right vs. left), a higher level of agreement regarding bilateral language representation is desirable for the MSI to replace the IAP for establishing dominance in preparation for epilepsy surgery.

*Epilepsia 46 Suppl. 8 :79 (Abst. 1.189) , 2005*

## **Introduction:**

The intracarotid amobarbital procedure (IAP) or Wada test has been used to clarify and establish hemispheric language dominance in preparation for epilepsy surgery since the 1950s. In recent years, functional neuroimaging techniques have offered the possibility of non-invasive language lateralization and language mapping, although reported concordance with the IAP varies considerably. Magnetoencephalography or magnetic source imaging (MSI) is one of the newest functional imaging techniques and has been used to localize seizure activity, somatosensory, and motor function as well as cortical language areas.

Studies of the relationship between IAP and MSI results are few to date. Breier et al. (2001) found an 87% concordance rate between the MSI and IAP in children ages 8-18 years (N = 19). Papanicolaou et al. (2004) also found an 87% concordance rate between MSI and IAP in a combined child and adult population (N = 100), while Doss et al. (2005) found a concordance rate of 81% when detecting the presence of language in the hemisphere being considered for treatment (N=21). The current study reports pediatric data comparing the IAP and MSI procedures for establishing language dominance.

## **Methods:**

A retrospective chart review was conducted of pediatric patients (ages 6-17 years) with intractable seizures from the Minnesota Epilepsy Group who had both IAP and MSI language activation studies since 1998 and within 12 months of the comparative procedure. Table 1 lists the group characteristics. None of the 11 subjects (9 males, 2 female) had previously undergone resective surgery.

The IAP was conducted at the Minnesota Epilepsy Group for all subjects according to a well-established protocol. Left hemisphere language dominance was determined by the subject's ability to produce and/or understand meaningful speech at maximal drug effect (i.e. zero motor response) following the right injection, combined with a demonstrated global aphasia following the left injection. Subjects showing an opposite pattern were classified as right hemisphere dominant, while those with evidence of language function in both hemispheres were called bilateral. Interpretation of the IAP results was performed without knowledge of MSI data.

Five subjects had the MSI study at the University of Texas Houston Health Science Center and six subjects had the MSI study at the Minnesota Epilepsy Group using the same language protocol. The procedure involved an auditory word-recognition task (Apple Macintosh, SuperLab software and sound amplification) reported previously (Papanicolaou et al., 2004). The MSI/MEG unit consists of a 148-channel Magnes 2500 WH system (4-D Neuroimaging, San Diego, CA). MSI language analysis was completed without knowledge of the IAP test results. The single equivalent current dipole (ECD) model was used in the analysis of language data and has been validated by other institutions. Clinical laterality judgments for the MSI were based on the number of dipoles or activation sites in each hemisphere using the formula  $(R-L/R+L)$ . Index values between  $-0.2$  and  $0.2$  were considered to denote bilateral language activation. Values

greater than 0.2 or less than  $-0.2$  were indicative of right or left hemisphere dominance, respectively (see Figures 1-3).

## **Results**

There were no cases in which results of the two procedures were completely discordant. Based on the criteria described, the IAP and MSI had a strict concordance rate of 64% (7 of 11), with four subjects being classified as left language dominance on both IAP and MSI and two subjects classified as bilateral on both procedures (see Table 2). The remaining 4 subjects were all classified as bilateral for language using one method and unilateral (left or right) on the other method. One subject was right dominant on the MSI and had a bilateral language representation on the IAP. The final three had bilateral language on MSI and left dominance on IAP. There was a concordance rate of 82% on MSI and IAP with regard to the presence or absence of language in the hemisphere to be treated.

## **Conclusions:**

- This study showed no completely discordant cases between MSI and IAP.
- Concordance between IAP and MSI is 82% in identifying the presence or absence of language in the hemisphere of proposed surgery consistent with other published reports.
- Disagreement between IAP and MSI classification is limited to subjects identified as bilateral for language with either method.
- These results suggest MSI may be a viable alternative to the IAP in children, although further study is needed to better define the bilateral language cases.

## **References:**

1. Breier JI, Simos PG, Wheless JW, Constantinou JE, et al. Language dominance in Children as Determined by Magnetic Source Imaging and the Intracarotid Amobarbital Procedure: A Comparison. *Journal of Child Neurology*, Vol. 16, Number 2, February 2001
2. Papinicolaou, A.C., et al (2004). Magnetoencephalography: a noninvasive alternative to the Wada Procedure. *Journal of Neurosurgery*, 100, 867-876.
3. Doss R, Zhang W, Risse G, Gates J. Language Lateralization: A comparison of magnetic source imaging to the Wada procedure. Paper presented: M.E.G. Applications Conference, Xylocastro, Greece, September 2005.

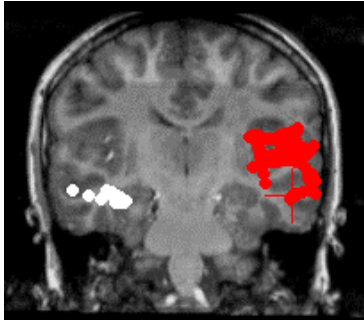
Table 1

### Group Characteristics

N	11
Gender (% Male)	82%
Handedness (% Right)	100%
	Mean (SD)
Age of Seizure Onset	6.23 (2.88)
Full Scale IQ (FSIQ)	92.5 (17.8)
Age at MSI	13.86 (3.44)
Age at IAP	13.32 (4.00)

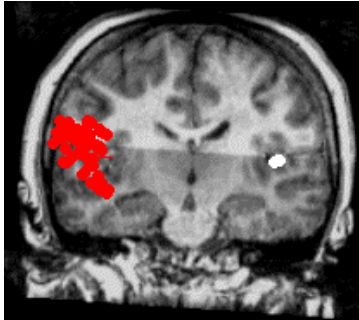
### MSI Language Laterality

Figure 1



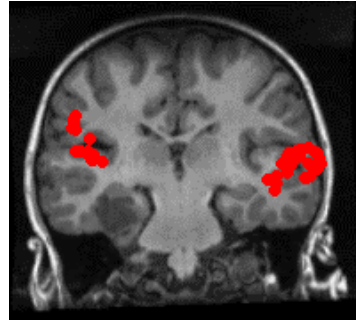
Left

Figure 2



Right

Figure 3



Bilateral

Table 2

### Concordance of IAP and MSI Language Laterality

		MSI		
		Left	Bilateral	Right
IAP	Left	4	3	0
	Bilateral	0	3	1
	Right	0	0	0

Concordance Rate = 64%

Table 3

**Concordance of IAP and MSI Language Laterality  
in the Hemisphere to be Treated**

		<b>MSI</b>	
		Language Present	Language Absent
<b>IAP</b>	Language Present	8	1
	Language Absent	1	1

Concordance Rate = 82%