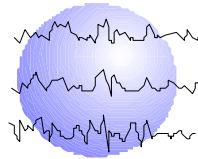


NAMING ABILITY AFTER TAILORED RESECTION WITH LANGUAGE MAPPING IN PATIENTS WITH LEFT HEMISPHERE TUMORS PRESENTING WITH EPILEPSY

Keith G. Davies, MD
Gail L. Risse, PhD
John R. Gates, MD



This paper has been prepared specifically for:
American Epilepsy Society Annual Meeting
Seattle, WA

December 6 - 11, 2002

Please consider this information to be preliminary findings.

Minnesota Epilepsy Group, P.A.[®]
225 Smith Avenue N., Suite 201
St. Paul, MN 55102-2534
Phone: (651) 241-5290
Fax: (651) 241-5248

REVISED ABSTRACT

PURPOSE

Temporal resection for non-lesional epilepsy in the left, language-dominant hemisphere carries the risk of decline in postoperative naming ability, and this risk is associated with later epilepsy onset age/absence of hippocampal sclerosis. The present study aimed to examine naming outcome after tailored resection of tumor and "epileptogenic" cortex, with extraoperative language mapping, in patients presenting with epilepsy due to left hemisphere tumor.

METHOD

The sample consisted of patients undergoing left hemisphere tailored resection after subdural grid placement who had Boston Naming Test (BNT) evaluation pre- and six to eight months postoperatively, and who had left hemisphere dominance for language by amobarbital testing. Reliable Change Index (RCI) (5 for BNT) was used as an indication of meaningful change.

RESULTS

Eleven patients (four male) were studied. Four had frontal and seven temporal resection. Mean age was 35 years (range 9 to 61 years) and mean epilepsy onset age 28 years (range 3 to 60 years). Mean BNT change for the frontal group was -1.25, and for the temporal group -15.0. For the frontal group one patient had a >RCI BNT decline, and for the temporal group five (71%) had a >RCI BNT decline. For the temporal group there was a significant correlation between BNT decline and onset age ($r=-0.9$, $p<0.01$). Later onset age was associated with greater decline. No relationship was found between BNT decline and number of language sites resected or distance between the edge of the resection and the closest language site.

CONCLUSION

Patients with temporal, but not frontal, lesional epilepsy undergoing tailored resection were at risk of confrontation naming decline. Later onset age was associated with greater BNT decline, similar to the finding for non-lesional resections.

INTRODUCTION

Anterior temporal lobectomy in the hemisphere dominant for language carries risks for impairing language function, specifically naming ability, after surgery. Other aspects of language function such as fluency and comprehension are typically unaffected. Although group comparisons show no or only modest decline, at increased risk is a subgroup with: later epilepsy onset age, absence of early risk factors for epilepsy, and absence of hippocampal sclerosis, all features of the absence of the syndrome of mesial temporal sclerosis.

Language mapping has been used as a technique to minimize the risk of producing language dysfunction after dominant hemisphere surgery. Mapping may be undertaken intraoperatively or extraoperatively, the latter also allowing ictal EEG monitoring in order that the resection may be maximized while preserving functional areas. Mapping has revealed that language sites are highly variable in distribution, and not confined to well-demarcated classical language areas. Naming has been shown to be at risk of decline for temporal resection in non-lesional cases even with language mapping [1].

When the epilepsy is due to tumor, ictal monitoring may be used to identify areas of "epileptogenesis" not necessarily coextensive with the tumor. It has been argued that resection of these areas offers a superior result over lesionectomy alone. When the tumor is in the language dominant hemisphere, mapping is required so that they may be preserved.

Proximity of the resection to language areas has been reported to be a risk factor for language deficit after resection in tumor cases. Haglund et al found that language deficits were fewer if the resection was >1cm from the nearest language site [2].

The present study aimed to examine naming ability after left, language dominant hemisphere resection of tumor and epileptogenic area with extraoperative language mapping and to identify potential risk factors.

MATERIAL AND METHODS

The patient sample was taken from a population of patients with intractable epilepsy due to tumor undergoing resection in the left, language-dominant hemisphere. After placement of a subdural grid, language mapping and localization of epileptogenic cortex was undertaken in each case. A resection aiming to maximize removal of tumor and epileptogenic cortex while preserving language areas was then undertaken. The following criteria were required: left hemisphere dominance for language as evaluated with an intracarotid amobarbital procedure; pre- and postoperative neuropsychology testing which included the BNT.

Neuropsychology Testing

Neuropsychology testing was performed preoperatively and six to eight months postoperatively. A comprehensive battery of tests was administered, including tests of language function, intelligence and memory. For the purposes of this study the 60-item BNT was used.

Reliable Change Index (RCI) (5 for BNT) was used as an indication of meaningful change in BNT score.

Language Mapping Technique

Language mapping was performed once the ictal onset had been clarified and this was undertaken in at least two sessions, aiming to locate areas with consistent language responses. For the first patients, language sites were identified by stimulation interruption of spontaneous speech (speech arrest). More recently, a more extensive battery of language modalities has been performed, testing for spontaneous speech, visual naming, reading, repetition and comprehension. For the purposes of this study, language sites were then identified on the basis of stimulation interruption of any one of these modalities. One patient had no language sites identified with stimulation.

Surgical Technique

The craniotomy was always performed with general intubation anesthesia. In the first procedure, a subdural grid placed on the convexity of the hemisphere. In addition, subdural strip electrodes were placed beyond the edges of the grid to cover subtemporal, anterior frontal and subfrontal areas. Extraoperative monitoring and mapping was aimed at identification of epileptogenic cortex and language areas. At the second procedure the intention was removal not only of tumor but also epileptogenic cortex, while sparing language eloquent areas. These were identified as a collection of consistent language error sites based on mapping, but occasionally isolated single sites where language errors occurred in response to stimulation were identified. Such sites were not always spared. Mesial temporal structures were removed in four and preserved in three of the temporal cases.

Pathology

The pathology was low grade intrinsic tumor in each case: oligodendroglioma in six, ganglioglioma in three, oligoastrocytoma in two, and subependymoma in one.

RESULTS

None of the patients were clinically dysphasic postoperatively. Patients undergoing frontal resection were stable with regard to BNT score (Table and Figure 1). Those undergoing temporal resection suffered a BNT decline, with a mean decline of 15, and 5/7 a >RCI decline.

Temporal resections

There was a significant correlation between BNT decline and onset age ($r=-0.9$, $p<0.01$). Later onset age was associated with greater decline (Figure 2). There was no significant correlation between BNT decline and age or duration of epilepsy.

There was no significant correlation between BNT decline and: distance between the edge of the resection and the closest language site, total number of language sites, and number of language sites resected. There was no significant difference in BNT decline between patients undergoing resection or preservation of mesial structures.

In a multiple regression analysis with backward entry of variables with BNT decline as the dependent variable and onset age, preoperative BNT score, total number of temporal language sites, distance from edge of resection to closest language site, and number of language sites resected, onset age emerged as the only significant predictor of BNT decline ($F=15.16$, $p<0.05$).

CONCLUSIONS

Patients with temporal, but not frontal, lesional epilepsy undergoing tailored resection were at risk of confrontation naming decline. This decline was associated with later onset age but not mapping-related factors such as resection of isolated language sites and proximity of language sites to the edge of the resection.

These findings are similar to those for non-lesional resections. The tumors were in general low grade and may have been present for several years, thus possibly resulting in reorganization of language function and stability of naming for the early onset age group.

REFERENCES

1. Davies KG, Risse GL, Gates JR. Naming ability after tailored left temporal resection with extraoperative language mapping: greater risk of decline with later epilepsy onset age [abstract]. *Epilepsia* 2001;42(Suppl 7):243-244.
2. Haglund MM, Berger MS, Shamseldin M, Lettich E, Ojemann GA. Cortical localization of temporal lobe language sites in patients with gliomas. *Neurosurgery* 1994;34(4):567-76.

TABLE**Patient data. Means (SDs)**

	Total N=11	Temporal N=7	Frontal N=4	P
Age (years)	35.2 (17.47)	32.9 (18.05)	39.3 (18.2)	NS *
Onset age (years)	28.2 (17.0)	22.1 (14.46)	38.7 (17.65)	NS *
Duration of epilepsy (years)	6.9 (10.64)	10.7 (11.95)	0.3 (0.47)	NS *
Sex M/F	5/6	3/4	2/2	NS †
Preoperative BNT score	49.91 (9.19)	45.7 (8.32)	57.3 (5.50)	<0.05 *
BNT score change	-10.0 (14.22)	-15.0 (15.93)	-1.3 (2.50)	NS *
BNT >RCI decline	6	5	1	NS †

* *t test of independent samples*

† *chi-square test*

Figure 1 Change in BNT score for temporal and frontal resections. The dashed line indicates RCI score (-5).

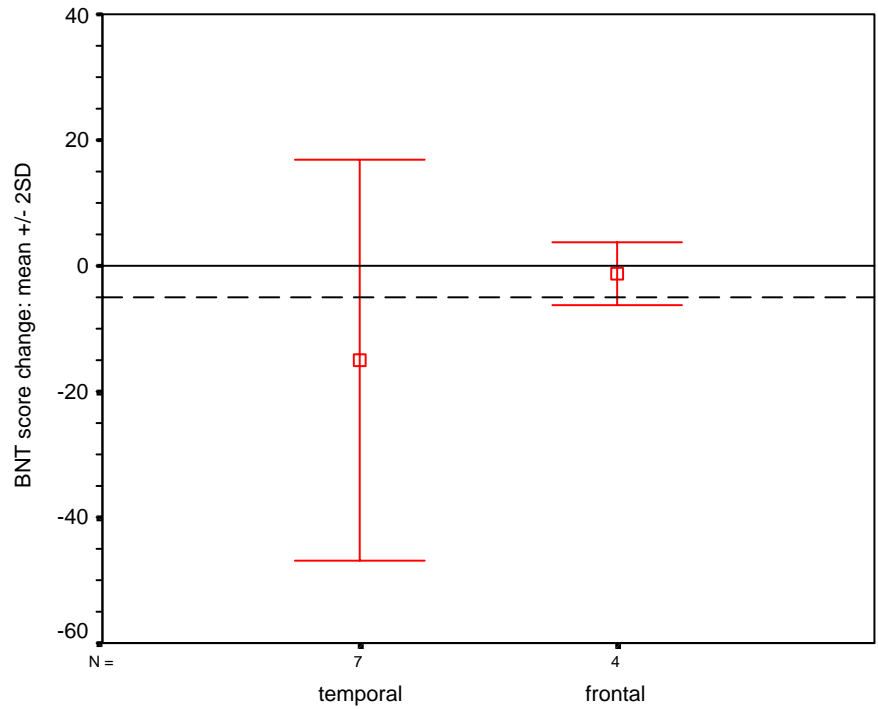


Figure 2 BNT score change according to onset age. The dashed line indicates the RCI change (-5).

